

# The Avian Gastric Yeast Experience

Belinda Brice  
Kanyana Wildlife Rehabilitation Centre  
120 Gilchrist Road, Lesmurdie, 6076, Perth, Western Australia  
Email: lindy.brice@yahoo.com.au

## ABSTRACT

The Ascomycetes yeast *Macrorhabdus ornithogaster* is an organism that can only grow at the juncture between the proventriculus and ventriculus in birds. A wide variety of bird species, including Australian native parrots, can become infected with *M. ornithogaster*. It was originally thought that this organism was a large bacterium, hence the name “megabacteria” but recent studies suggest that it is actually a yeast. It is sometimes referred to as “avian gastric yeast ” or “AGY” and is sometimes, but not always, associated with a chronic wasting disease.

Approximately 2800 animals are admitted to the Kanyana Wildlife Rehabilitation Centre, Perth every year, of which about 16% are parrots. Since 1994, Kanyana has had a team of experienced microscopists who conduct microscopic examinations on the faeces of many of the animals that are admitted into the centre. Faecal samples are routinely collected from parrots on admission and screened for AGY. In-house microscopy has been found to be a useful tool to aid in the identification and treatment of parrots with AGY. Incidence rates and disease trends amongst various parrot species will be discussed as well as the current treatment regime used at Kanyana Wildlife Rehabilitation Centre. Case studies will also be presented.

## INTRODUCTION

Approximately 2800 animals are admitted annually to the Kanyana Wildlife Rehabilitation Centre, Perth, of which about 16% are parrots. Since 2000, Kanyana has had a team of volunteers who conduct microscopic examinations on the faeces of many of the animals that are admitted into the centre. During 2014/2015, 824 parrots (comprising rainbow lorikeets, galahs, red-capped parrots, Australian ringnecks and little corellas) were admitted into the centre. We try to do a direct smear on the faeces of all parrots as soon as possible after admission.

Avian gastric yeast (AGY) only grows in the gastric isthmus of a bird’s stomach (the junction between the proventriculus and ventriculus) (Tomaszewski et al., 2003). It was originally thought to be yeast (Dorrestein et al., 1980) because of the way it stained. Later, others concluded that it was a large bacteria-like organism (van Herck, 1984; Scanlan and Graham, 1990), hence the name “Megabacteria”. In 2003, Tomaszewski et al. genetically characterized the organism and proved that it is yeast. It is sometimes referred to as “AGY” but now it is known as *Macrorhabdus ornithogaster*. Birds infected with AGY often show signs of a chronic wasting disease. In budgerigars the chronic wasting condition is seen most commonly in middle-aged birds and is called “going light” (Baker, 1985).

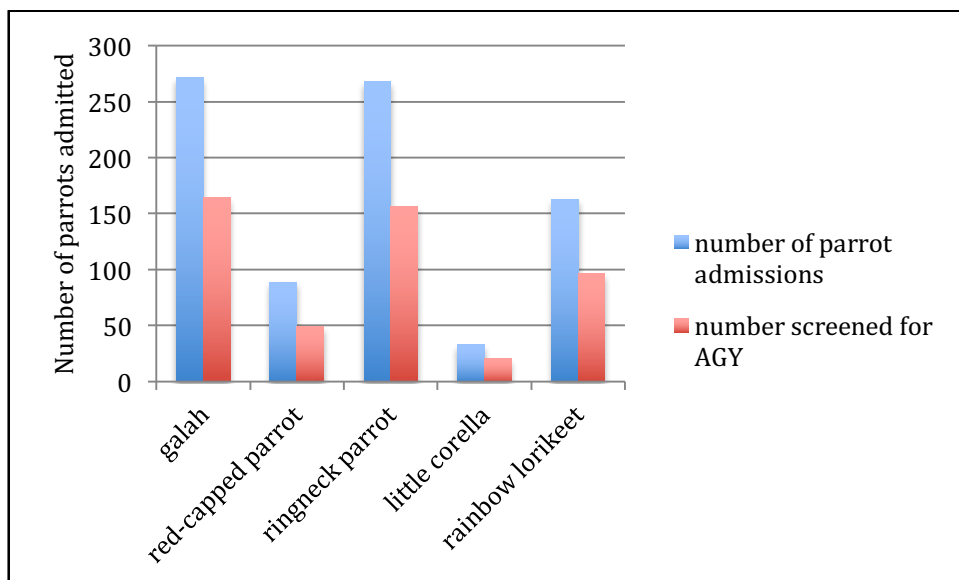
## HOST RANGE

AGY infects many different species of birds (van Herck et al., 1984), including a wide range of psittacine birds. It has been found worldwide in both wild and captive-bred birds of all ages (Dorrestein et al., 1980; Phalen, 2005; Martins et al., 2006). AGY is common in captive-raised budgerigars, finches, lovebirds and canaries. It has also been reported in chickens, quails, partridges, turkeys, ostriches and rheas (Martins et al., 2006).

At Kanyana, we have identified the organism in a pet budgerigar (*Melopsittacus undulates*), weiros (*Nymphicus hollandicus*), Japanese quails (*Coturnix japonica*), Gouldian finches (*Erythrura gouldiae*), galahs (*Eolophus roseicapillus*), Australian ringneck parrots or twenty-eights (*Barnardius zonarius*), red-capped parrots (*Purpureicephalus spurius*), little corellas (*Cacatua sanguinea*), western rosellas (*Platycercus icterotis*), rainbow lorikeets (*Trichoglossus haematodus*) and domestic canaries (*Serinus canaria*). To date we have not seen AGY in any other wild bird species including red-tailed black-cockatoos (*Calyptorhynchus banksii*), Carnaby's black-cockatoos (*Calyptorhynchus latirostris*), common bronzewing pigeons (*Phaps chalcoptera*), domestic pigeons (*Columba livia*), laughing turtle-doves (*Streptopelia senegalensis*) and spotted turtle-doves (*Streptopelia chinensis*).

Of the 824 parrots admitted, 485 (59%) were screened for parasites, including AGY (see Chart 1 below). The other 41% of parrots either died before a faecal sample was collected or were euthanased on admission. Approximately 22% of the parrots admitted to Kanyana were admitted due to illness, 19% were admitted due to trauma of unknown origin, 23% were admitted as a result of being struck by a motor vehicle, 6% due to domestic animal attack and 17% were admitted with their reason of admission being unknown. The remaining parrots (13%) were admitted due to other reasons such as impact injury, displaced due to habitat destruction, escaped pet or poisoning.

**Chart 1: Parrot admissions for 2014/2015**

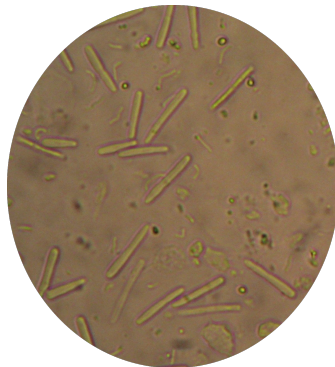

## THE AGY ORGANISM

It is thought that AGY was introduced into the Eastern states of Australia in the early 1990's through the importation of exhibition budgerigars. It has gradually spread across Australia. AGY was first detected at Kanyana in 1997 by Ruth Haight (former Kanyana volunteer and veterinary nurse) in a galah with diarrhoea and weight loss.

The organism was first described in 1980 (Dorrestein et al., 1980). It is a long, slender, cigar shaped organism. The ends are rounded and are narrower at one end. These Gram-positive organisms can be variable in shape and size and are very occasionally seen in a y-shaped form. They are approximately 20 to 80µm in length and are 2 to 3µm in width. When seen in a wet mount, small refractile nuclei can be seen at regular intervals (Phalen, 2014).

Photograph 1: AGY as seen under the microscope (400X magnification)



The organism can be cultured from faeces or isthmus scrapings (Hanafusa et al., 2007). AGY can be grown *in vitro* if a suitable substrate and special conditions are provided. It grows best at pH 3-4, at a temperature of 42°C and in microaerophilic conditions (lower than atmospheric oxygen concentration).

## TRANSMISSION

Spread of the AGY organism is probably via the faecal-oral route. Altricial nestlings (young that are born helpless) may also be infected when their parents regurgitate food for them. Many AGY infected birds are asymptomatic but still shed the organism (Phalen et al., 2002). It is therefore important to try to screen all parrots that are admitted into wildlife rehabilitation centres so that infected birds can be isolated from AGY negative birds. AGY is unable to infect mammals (Hanafusa et al., 2013).

## CLINICAL SIGNS

The clinical signs of AGY have been well described in the literature (Dorrestein et al., 1980; Phalen, 2005). The most common signs are prominent keel, fluffed feathers, depressed appearance, vomiting, regurgitation of crop contents, diarrhoea and weight loss. The incubation period ranges from weeks to years so some birds may only show clinical signs a few years after infection. This is often the case with infected budgerigars (Simpson, 1992) whilst growing ostrich chicks show signs of illness early on (Huchzermeyer and Henton, 1993). Some birds display no symptoms at all but are positive for AGY. These birds may well go on to display symptoms in the future.

Birds that have advanced AGY infection appear very thin or emaciated on admission. Their symptoms are related to the damage the organism does to the lining of the proventriculus and ventriculus. They are also “fluffed up” and depressed, some are very weak, they regurgitate their food and their vents are stained with faecal material. Faeces can be varied (slightly loose to diarrhoea) and are often bulky and pale. The faeces often contain undigested seeds. Ground-up seeds are often seen in the seed bowl as the bird is grinding the seeds but not actually able to digest the food properly. Vomiting (sometimes with blood or mucous) is often seen during the late stages of the illness. During this stage of the illness the faeces is often stringy dark green or tarry and black. The bird dies as a result of weight loss or from bleeding from ulcers in the stomach lining. Many of the infected birds that are admitted into Kanyana display these advanced symptoms of AGY infection. Members of the public bring in these birds as many are found on the ground and are unable to fly due to the wasting away of their breast (pectoral) muscle.

Some birds have concurrent infections with AGY as well as other diseases such as psittacine beak and feather disease virus (PBFDV). We regularly see this at Kanyana amongst twenty-eight parrots and galahs. The PBFDV acts as an immunosuppressant and hence reduces the hosts resistance to AGY and other infections. The number of little corellas co-infected is particularly high. All 6 AGY positive little corellas admitted to Kanyana were also displaying symptoms of PBFDV. In addition, another 6 birds (not tested for AGY) were euthanased due to PBFDV. In total, 12 out of 33 (36%) little corellas admitted were definitely showing signs of PBFDV. This figure is lower than that reported by Raidal et al. in 1993. In this study, 4 out of 6 (66,6%) short-billed corellas were found to be seropositive for PBFDV.

Birds may also be suffering from other diseases that have similar symptoms to that of AGY infection. These include heavy metal poisoning, trichomoniasis, giardiasis, bacterial and other fungal infections of the crop and stomach as well as gastric foreign bodies (Australian Wildlife Health Network).

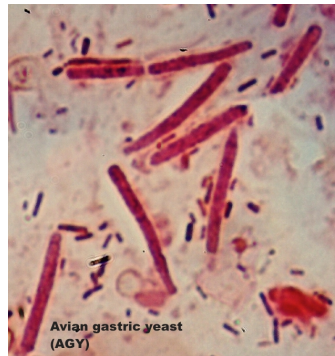## **DIAGNOSIS**

### **In a live bird**

AGY can be seen in crop washings (a less sensitive site) and faeces of many infected birds. AGY detection at Kanyana is done by microscopic examination of a wet mount of fresh faeces. A slurry is made with a small portion of faeces and saline and this is examined using the 20X and 40X objective (see Photograph 1 on previous page).

Stained smears (Gram staining or a quick stain) of faeces can also be done but we have not found this to be necessary (see Photograph 2 on the following page). Unlike bacteria and other yeasts, the contents of the yeast cell stain, but not the cell wall. AGY does not stick well to glass slides unless the slide has been heat fixed (Phalen, 2014). Proventricular scrapings from post mortem (PM) cases can also be examined (see Photograph 3 on the following page).

Photograph 2: AGY stained with a Gram stain

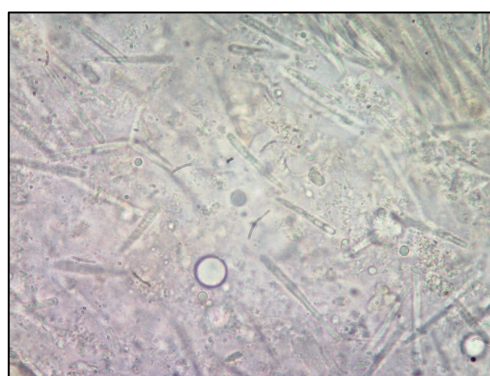

Birds that are infected with AGY may shed the organism in high numbers, low numbers or even not at all (Phalen, 2005). We have found that if the bird is ill and showing AGY symptoms then usually, many organisms can be seen. However, we have also had cases where only 1 or 2 organisms are seen per field or even on an entire slide so one needs to screen slides carefully to ensure that the AGY organisms are not missed. Intermittent shedding of the AGY organism also means that false negatives may occur. For this reason, periodic faecals should be examined. If a faecal is negative for AGY and the bird is showing symptoms it does not indicate that the bird is free of AGY infection. Faecal smears may be insensitive as a means of diagnosis but as there is no polymerase chain reaction (PCR) AGY test available in Australia at this time, we have no other option at the moment.

### **Postmortem diagnosis**

A scraping can be made from the junction of the proventriculus and the ventriculus and this is likely to show the organisms in large numbers (van Herck, 1984). Simply finding the AGY organism does not prove that it was the cause of death. Tissue sections of the isthmus can be stained with hematoxylin and eosin to demonstrate the organisms. They are often found in a characteristic “log-jam “ pattern (Phalen, 2014). One may also see the thickened walls of the proventriculus on postmortem and excess mucous may sometimes be seen in the lumen (Baker, 1985). Bleeding ulcers may sometimes be seen as well (Phalen, 2014).

Photograph 3: Scraping from the proventriculus made at post mortem of a ringneck parrot admitted to Kanyana



## **HUSBANDRY AND HYGIENE**

Even though AGY has a limited survival time once outside a bird's body, good husbandry practices and strict hygiene measures should be undertaken when dealing with any sick bird. Infected birds need to be housed separately and basic barrier nursing needs to take place. Infected birds need to be cleaned, treated and fed last to reduce the chance of cross infection.

Every cage/hotbox must be thoroughly cleaned and disinfected daily so as to remove any faeces, vomit or regurgitated material. All items from the cage or hotbox, including perches, food bowls, plastic tubes/crop needles and syringes used to feed/treat infected birds, need to be washed in hot, soapy water, rinsed and then disinfected after each use. Plant browse needs to be changed daily. At Kanyana we routinely use F10® SC veterinary disinfectant ([www.healthandhygiene.co.za](http://www.healthandhygiene.co.za)). Clean handling towels are used each time for each bird. One also needs to wash and disinfect one's hands before and after handling each bird.

## **TREATMENT**

There have been a few trials done looking at the treatment of birds with AGY infection (Phalen DN, 2005; Filippich LJ and Perry RA, 1993).

Amphotericin B is the drug that is most often used to treat AGY infections. This antifungal drug seems to be safe and effective. Amphotericin B is a polyene macrolide antifungal which binds sterols, especially ergosterol in the cell wall of the fungus. This alters the permeability of the fungal cell wall leading to fungal death. Amphotericin B is not systemically absorbed from the gastrointestinal tract after it has been given orally. It can therefore be given in much higher doses compared to the intravenous route. Many different dosages have been recommended. At Kanyana we use a dose rate of 50mg/kg (as per Wattle Grove Veterinary Hospital, Perth). Phalen has used 100mg/kg, twice a day for 14 days but is now using 25mg/kg, twice a day (Phalen, 2014).

On finding a bird AGY positive at Kanyana, treatment is implemented if the bird is not looking too debilitated. All AGY positive birds are housed in our Isolation facility. We have found that if a sick AGY positive bird is not treated, it will die. Birds that are emaciated do not respond to treatment and these birds are euthanased on admission. Experience has shown that if the body weight of a chronically ill galah is below 200g, the bird will die, so we have a policy to euthanase these birds on admission.

Kanyana uses Fungilin™ (Amphotericin B) lozenges (Bristol-Myers Squibb) that are intended for human use. Your veterinary surgeon will have to supply you with a prescription to obtain them. They are given twice a day (BID) for 20 days. The lozenges are convenient to use when treating individual birds. Fungilin™ is administered directly into the crop by plastic tube or crop needle. The lozenges do not dissolve totally in the added liquid. A 5 or 10ml syringe is then used to draw up as much of the medication as possible. A flexible, soft, lubricated plastic tube is then attached to the syringe and the medication is given directly into the empty crop. It is vital that the medication is given on an empty crop so all food needs to be removed at least 30 minutes before the medication is administered and it must be put back 30 minutes after treatment.

It is important to also weigh the bird daily. It is necessary to give supplementary feeding to these ill AGY positive parrots. We normally tube feed them 2 to 4 times a day (depending on their age and weight). Birds normally start to regain their appetite in 3 to 5 days after treatment begins. Soluvet (Vetafarm, New South Wales) is added to their drinking water whilst they are on Fungilin™ treatment. This is to ensure that vitamin levels (especially vitamin D) are maintained whilst the birds are indoors for an extended time with no access to sunlight. They are not given parrot seed or grit whilst they are on treatment. This is because their gastrointestinal tracts are very sensitive and bleeding might occur if they are fed any hard seeds and grit. Instead we give them dove seed and rolled oats until they recover.

It is also very important to reduce stress on the sick bird. It is best to reduce access to the area they are housed in, keep the area quiet and cover the heated hotbox with a curtain for the bird to hide behind. We keep adult birds at 30°C and fledglings at 33°C. We do not give fruits that ferment easily like grapes or melon. We normally give AGY birds a chunk of apple and a piece of orange daily. Broad-spectrum antibiotics may need to be given to control any secondary bacterial infection if the bird is very sick. Probiotics may also be helpful post antibiotic treatment.

A study by A. Gestier showed that treated budgerigars became faecal negative for AGY within 5 days after being given water medicated with Amphotericin B and cyclodextrin (makes the Amphotericin B water soluble). At Kanyana, if after 7 days the bird has improved and is looking well, a faecal sample can be screened for AGY. If no AGY are seen in the faeces, the bird can be moved into a larger cage outside of the isolation unit, but it *must complete the entire course* of treatment. During this time it must still be housed separately and not with other birds. Many sick birds spend the entire treatment time in the isolation unit. The faeces must be tested again about 5-7 days post 20 days of treatment. Depending on the result, the bird is moved outside to a large flight aviary or medication continued. Only rarely do we see a bird that is still shedding AGY 20 days post Amphotericin B treatment. In our experience approximately 99% of previous AGY positive birds are negative post treatment. Treated birds may well relapse after release, particularly during stressful periods such as breeding. Whether they remain negative or start shedding the AGY organism after release is not known. More research is needed to ascertain if these treated birds are cured or if they continue to shed AGY at very low levels. On average, previously AGY positive birds are released 4-6 weeks after initial admission to Kanyana.

### **INCIDENCE OF AGY POSITIVE PARROTS AT KANYANA**

The distribution of AGY amongst wild birds in Australia is not known. AGY has been detected in Australian sulfur-crested cockatoos, wild galahs and feral European goldfinches on the eastern Australian coast (Filippich et al. 1993; Doneley B, 2012).

At Kanyana we regularly see wild galahs, ringneck parrots and red-capped parrots that are AGY positive. 24% of galahs, 29% of ringneck parrots, 16% of red-capped parrots and 30% of little corellas were AGY positive over the 2014/2015 period. Many of these birds show signs of illness on admission. Interestingly, the incidence of AGY in wild rainbow lorikeets in the Perth area is much lower than that found in other parrot species (see Chart 2 below).

L. Baird (Chelonia Wildlife Rehabilitation and Release) undertook a study in the Broome area in 2005/2006. The study showed that many Northern rainbow lorikeets were found to be positive for both AGY as well as coccidia. We have not found that this is the case in the Perth area. A recent study done at Kanyana revealed a prevalence of 22% for coccidian oocysts (11 out of 50 birds tested). None of these coccidia positive wild rainbow lorikeets were AGY positive. We have only seen AGY in one out of 96 rainbow lorikeets during 2014/2015 and this bird was negative for coccidia. The coccidia from the rainbow lorikeets were morphologically and phylogenetically characterized and identified as *Eimera haematodi* (Yang et al., 2015).

None of 131 samples from black cockatoos tested were AGY positive. The majority of these samples were from cockatoos housed at the Karaakin Black Cockatoo Conservation Centre, Perth. This centre does an amazing job rescuing and rehabilitating injured black cockatoos.

Chart 2: Number of AGY positive parrots seen at Kanyana during 2014/2015

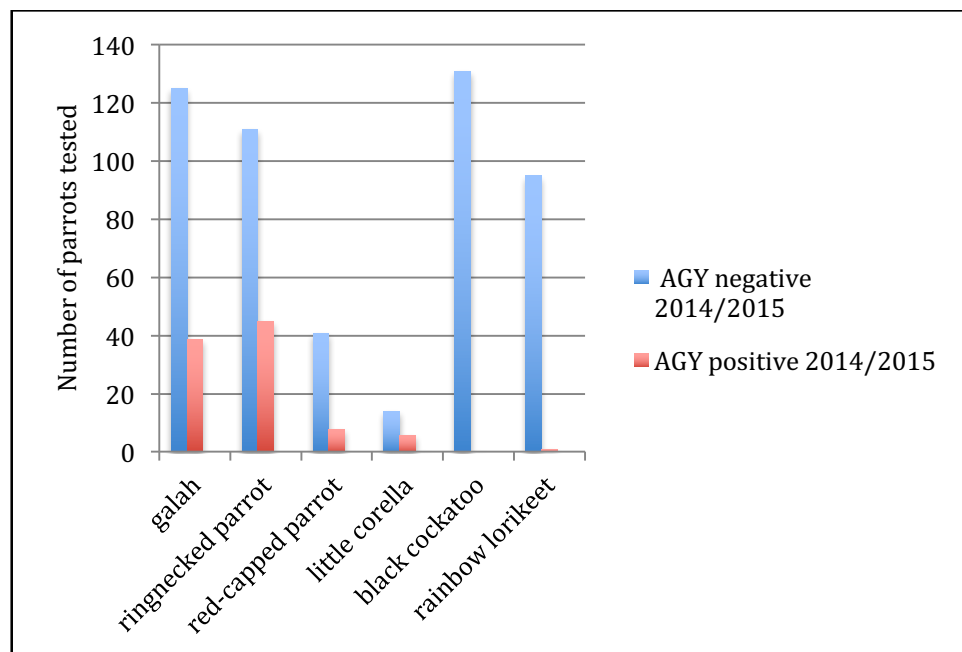




Table 1. Prevalence rate of AGY in different parrot species admitted to Kanyana (figures by Haight and Brice)

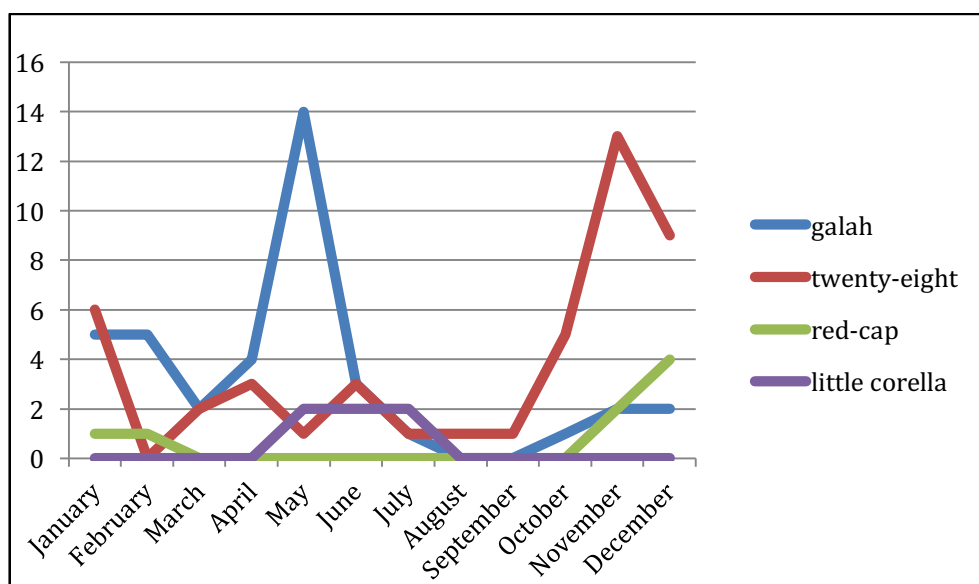
year of admission	ringneck parrot	galah	red-capped parrot	rainbow lorikeet
2007	24%	8%	14%	0%
2008	29%	20%	13%	0%
2009	16%	22%	15%	2%*
2010	15%	21%	15%	3%
2011	21%	12%	21%	5%
2012	22%	9%	13%	4%
2013	36%	13%	14%	0%
2014/2015	29%	24%	16%	1%

\* first AGY-positive rainbow lorikeet seen at Kanyana by R. Haight

### AGY Trends seen at Kanyana

During the months of October and November we tend to see higher numbers of newly fledged ringneck parrots (twenty-eights) and red-capped parrots with AGY infection. In the colder months of April, May and June, AGY is predominately found in galahs. In 2012 Donely described a weight loss syndrome in juvenile wild galahs in Queensland. They were all emaciated and suffering from diarrhoea. Many of the birds died despite being given supportive care, much as is the case seen at Kanyana. Two suspected pathogens were identified namely AGY as well as *Spirochela* spp.

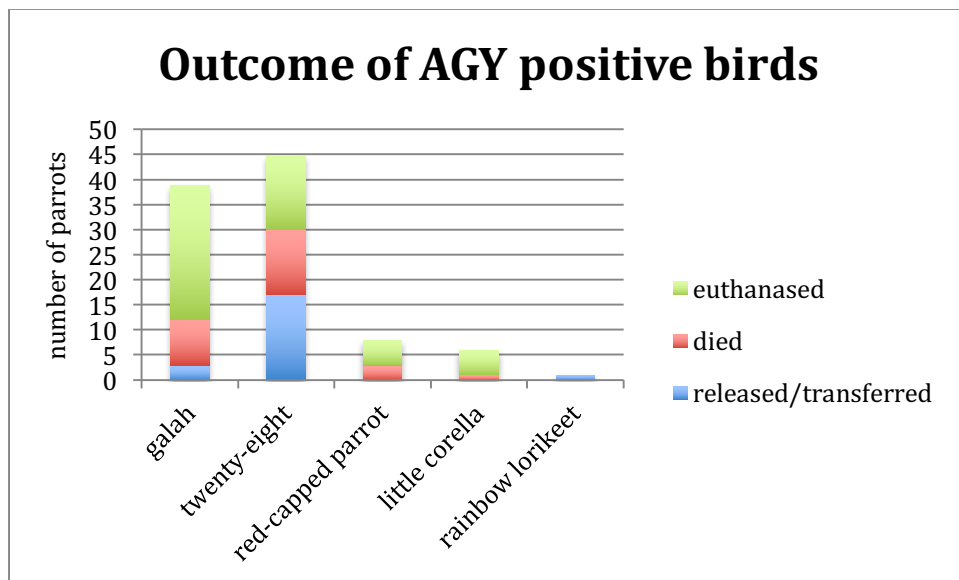
Chart 3: AGY positive parrot admissions by month



## OUTCOME OF AGY POSITIVE PARROTS AT KANYANA

Outcome of AGY positive parrots at Kanyana can be seen in Chart 4 below. Unfortunately, the majority of AGY positive parrots died or had to be euthanased on admission. Just under 8% (3/39) of previous AGY positive galahs and 38% (17/45) of ringneck parrots were successfully released back into the wild. Unfortunately, all previous AGY positive little corellas and red-capped parrots were euthanased or died.

Chart 4: Outcome of AGY positive parrots by species



## CASE STUDIES OF A FEW AGY POSITIVE BIRDS ADMITTED TO KANYANA

### Case study 1

A juvenile ringneck parrot was admitted to Kanyana after it was found immersed in a trough of water. On initial examination it had a body condition score of 2/5 (136g). It was noted that the tail and primary feathers showed colour variations that may have been attributed to an infection with PBFDV or could also have been as a result of a nutritional problem. No AGY was seen in the initial faecal sample tested. Over the following 2 weeks the bird lost about 22% of its body weight. The faeces became mucoid and it developed a very dirty vent. Another faecal sample was taken and this sample contained AGY, *Entamoeba* cysts and large numbers of white cells. The bird was started on a course of Flagyl<sup>TM</sup> (0,15ml/100g body weight) as well as Fungilin<sup>TM</sup> BID for 20 days. Blood was taken a week later and found to have a packed cell volume of 50 and a white cell count of 10000. A PBFDV PCR test came back as negative. The bird continued to improve and was transferred into home care after treatment. It was successfully released a few weeks later.

## Case study 2

An extremely emaciated galah was admitted in December 2014. On admission it weighed 183g. A chronic illness was suspected as the bird was extremely weak, was emaciated and had a very dirty vent. Further examination revealed symptoms of PBFDV so the bird was euthanased. AGY was found in large numbers in the faeces as well as a scraping from inside the proventriculus on post mortem (see Photograph 3).

## CONCLUSIONS

We have shown that AGY is found in approximately 20% to 30% of wild galah and ringneck parrots and around 16% of red-capped parrots admitted to Kanyana. A much lower incidence rate is seen in wild rainbow lorikeets (1%).

Wildlife carers wanting to care for these birds need to think carefully before doing so themselves. They need to make sure they have the necessary skills and time to do so. AGY positive birds increase the workload of volunteers (both independent carers and those working at rehabilitation centres) immensely. Quarantine and barrier nursing principles need to be carried out, all adding to the time it takes to care for these birds.

Further research is needed to assess the impact of this disease on wild bird populations in Australia. There is also the concern that AGY might spread from the wild bird population into chickens on free-range farms so this is another area of study that needs to be addressed.

## ACKNOWLEDGEMENTS

I wish to thank June Butcher and the volunteers at the Kanyana Wildlife Rehabilitation Centre for their commitment and dedication in caring for all the animals admitted to the centre. I am also grateful to the veterinarians and staff at the Wattle Grove Veterinary Hospital, Perth for their expert treatment and care of the wildlife treated at their clinic. A huge thank you to Ruth Haight for starting up the microscopy section at Kanyana and teaching me so much. I would also like to thank all the past and present Kanyana volunteers who have done microscopy at Kanyana, especially Dr Gerry Waneck, Keiran Jackson, Gwyn Raubenheimer, Merryn Pryor, Dr Amber Leonard, Pauline Hewitt and Nathan Jardine. A special thank you to Gwyn Raubenheimer for all her hard work, dedication and support in helping run the microscopy section.

## REFERENCES

1. Australian Wildlife Health Network.  
<https://wildlifehealthaustralia.com.au/FactSheets.aspx>
2. Baird L. Avian gastric yeast (formerly known as Megabacteria). 2006.  
<http://www.multiculturalwa.net.au/chelonia>
3. Baker JR. 1985. Clinical and pathological aspects of “going light” in exhibition budgerigars (*Melopsittacus undulates*). *Veterinary Record* 116: 406-408.
4. Doneley B. Weight loss syndrome in juvenile free-living galahs. 2012. *Proceedings Annual Conference Australasian Association of Avian Veterinarians and Unusual and Exotic Pet Veterinarians*. 9-11.
5. Dorrestein GM, Zwart P, Buitelaar MN. 1980. Problems arising from disease during periods of breeding and rearing canaries and other aviary birds. *Tijdschrift voor Diergeneeskunde*. 105(13): 535-543.

6. Filippich LJ, Boyle DA, Webb R and Fuerst JA. 1993. Megabacteria in birds in Australia. *Australian Veterinary Practitioner* 23: 71-76.
7. Filippich LJ and Perry RA. 1993. Drug trials against megabacteria in budgerigars (*Melopsittacus undulates*). *Australian Vet Practice* 23: 184-189.
8. Gestier AW. Megabacteria in budgerigars. Article from Vetafarm research Facility, Wagga Wagga, Australia. (<http://www.world-budgerigar.org/article1.htm>).
9. Hanafusa Y, Bradley A, Tomaszewski EK et al. 2007. Growth and metabolic characterization of *Macrorhabdus ornithogaster*. *Journal of Veterinary Science and Medical Diagnosis* 19: 256-65.
10. Hanafusa Y, Costa E, Phalen DN. 2013. Infection trials in mice suggest that *Macrorhabdus ornithogaster* is not capable of growth in mammals. *Medical Mycology* 51: 669-72.
11. Huchzermeyer FW, Henton MM, Keffen RH. 1993. High mortality associated with megabacteriosis of proventriculus and gizzard in ostrich chicks. *Veterinary Record* 133: 143-144.
12. Martins NR, Horta AC, Siqueira AM et al. 2006. *Macrorhabdus ornithogaster* in ostrich, rhea, canary, zebra finch, free range chicken, turkey, guinea-fowl, columbina pigeon, toucan, chuckar partridge and experimental infection in chicken, Japanese quail and mice. *Arquivo Brasileiro de Medicina Veterinaria e Zootecnia* 58 (3): 291-8.
13. Phalen DN, Tomaszewski E, Davis A. 2002. Investigation into the detection, treatment and pathogenicity of avian gastric yeast. *Proceedings Association Avian Veterinarians*, 2002: p 49-51.
14. Phalen DN. 2005. Diagnosis and management of *Macrorhabdus ornithogaster* (formerly megabacteria). *Veterinary Clinics: Exotic Animals* 2005; 8: 299-306.
15. Phalen DN. 2014. Update on the diagnosis and management of *Macrorhabdus ornithogaster* (formerly Megabacteria) in avian patients. *Veterinary Clinics: Exotic Animals* 17: 203-210.
16. Raidal SR, Mc Elnea CL and Cross GM. 1993. Seroprevalence of psittacine beak and feather disease in wild psittacine birds in New South Wales. *Australian Veterinary Journal* 70 (4): 137-139.
17. Scanlan CM and Graham DL. 1990. Characterization of a gram-positive bacterium from the proventriculus of budgerigars (*Melopsittacus undulates*). *Avian Disease* 34: 779-86.
18. Simpson VR. 1992. Megabacteriosis in exhibition budgerigars. *Veterinary Record* 131: 203-204.
19. Tomaszewski EK, Logan KE, Snowden KF, Kurtzman CP and Phalen DN. 2003. Phylogenetic analysis identifies the “megabacterium” of birds as a novel anamorphic ascomycetous yeast, gen.nov., sp. nov. *International Journal of Systematic Evolutionary Microbiology* 534: 1201-1205.
20. Van Herck H, Duijser T, Zwart P, et al. 1984. A bacterial proventriculitis of canaries. *Avian Pathology* 13: 561-72.
21. Yang R; Brice B and Ryan U. 2015. Molecular characterization of *Eimeria haematodi*, coccidian parasite (Apicomplexa:Eimeriidae) in a rainbow lorikeet (*Trichoglossus haematodus*). *Experimental Parasitology* 153: 123-128.

